



RESEARCH ARTICLE

What Causes Oxygen Deprivation of the Blood(DIC) and Then Lungs(SARS - CoV 2 & 12)?

Robert O Young*, Galina Migalko

Universal Medical Imaging Group, USA

Abstract

Oxygen deprivation in the blood and then lungs is the result of pathological blood coagulation or Disseminated Intravascular Coagulation (DIC) involving a cascade of protein factors leading to the excessive aggregation or symplasmism of the erythrocytes or red blood cells caused by several acidic contributing environmental, metabolic, respiratory and dietary factors [1].

Introduction:

The alveolus of the lung (plural: alveoli, from Latin alveus, "little cavity"), is a tiny structure within the lungs measuring approximately 200 micrometers, or just a fraction of a centimeter. These tiny alveoli are bunched together in grape-like clusters to form alveolar sacs. On the surface of the alveoli are networks of tiny blood vessels called capillaries (Figure 1). It is through these tiny capillaries that airway oxygen from the air you inhale diffuses into the blood stream as a result of partial pressure. At the same time, carbon dioxide, the waste product of respiration, moves from the capillaries into the alveoli and out through the airways of the lungs where it is blown out with the next exhalation [2].

When you are unable to inhale sufficient airway atmospheric oxygen (O₂), or if your blood or body cells are incapable of transferring or using oxygen properly, you can become hypoxic, or low oxygen in your organs, glands and tissues, or hypoxemic, with oxygen in your red blood cells. These two conditions are caused by oxygen deprivation due to pathological blood coagulation which is extremely hazardous to your health if allowed to continue untreated (Figure 2). If you have COPD, interstitial lung disease or any another acute or chronic breathing condition like asthma, your body will not be able to absorb airway oxygen or diffuse sufficient amounts into your blood or tissues. Without oxygen delivery to your body cells that make up your organs, glands and tissues the normal cell function is compromised and your health will be at serious risk [3].

Discussion:

Why the blood cannot pass into the alveolar sacs of the lungs?

One of the purposes of the red blood cells is to remove highly toxic and acidic cellular metabolic waste in the form of carbon

dioxide and lactic acid and to pick up oxygen for delivery to cells for normal functioning. The process is called cellular respiration or oxygenation which takes place in the alveolar sacs of the lungs.

In order for the red blood cells to remove acidic metabolic waste and to pick up life giving oxygen they must pass through the pulmonary vein and then into the capillary pools. If the red blood cells are in pathological coagulation or aggregation there is no way to enter. Why? Because the entry into the capillary venules that branch off from the pulmonary vein measure 3 to 5 microns (1 micron is 1/25,000 of an inch - See Micrograph 1) and a single red blood cell measures 7 microns which makes it impossible for the red blood cell to enter the capillary venules if they are aggregated or coagulated into groups of red blood cells! [4]

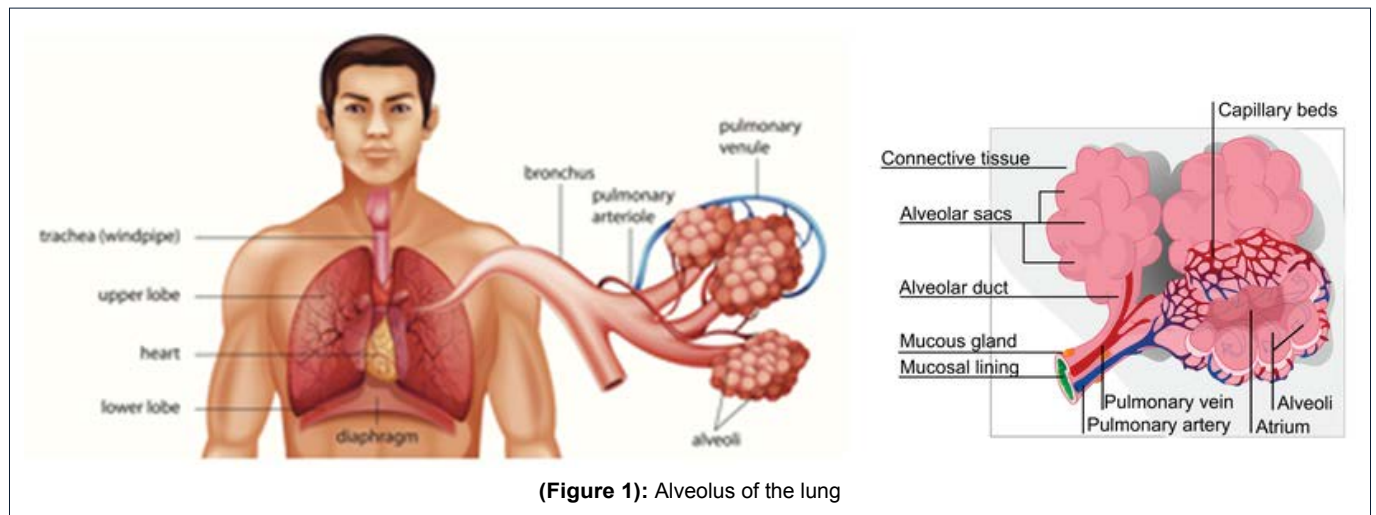
When red blood cells group or clot together into a fibrin net, a clotting protein created when there is injury to the cell membrane and/or endothelial cells that protect the lining of blood vessels, (See Picture 2) the red blood cells cannot enter into the pulmonary vein and then into the capillary pools to release their acidic carbon dioxide waste and pick up oxygen in the alveolus of the lungs (Figure 3) [5].

Pathological blood coagulation or disseminated intravascular blood coagulation (DIC) inside the pulmonary vein will prevent the free passage of red blood cells into the alveoli of the lungs via the pulmonary capillaries (Figure 4). Erythrocytes or red blood cells must go into the pulmonary capillaries single file. If they cannot pass into the pulmonary capillaries of the lung to

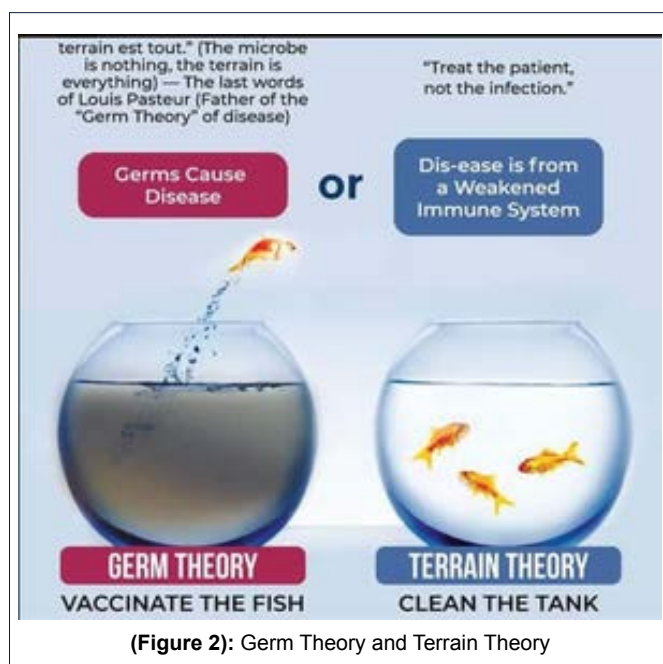
Correspondence to: Robert O Young, Naturopathic Practitioner, Universal Medical Imaging Group, USA; E-Mail: phmiraclelife[AT]gmail[DOT]com

Received: June 13, 2020; **Accepted:** June 16, 2020; **Published:** June 20, 2020

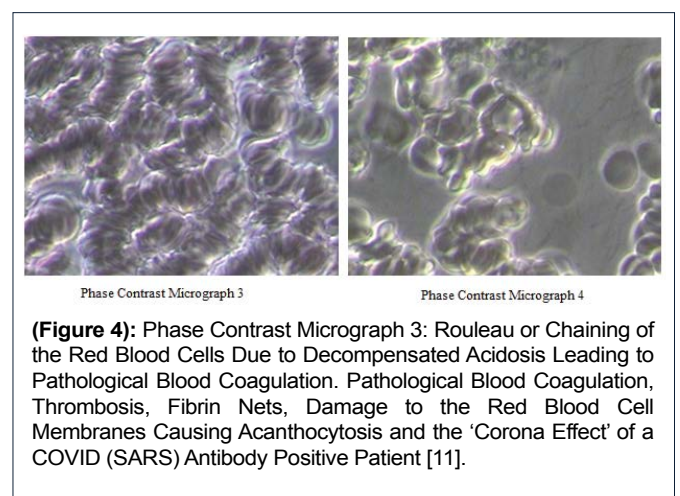
Reviewed by: Fedotova J



(Figure 1): Alveolus of the lung



(Figure 2): Germ Theory and Terrain Theory



(Figure 4): Phase Contrast Micrograph 3: Rouleau or Chaining of the Red Blood Cells Due to Decompensated Acidosis Leading to Pathological Blood Coagulation. Pathological Blood Coagulation, Thrombosis, Fibrin Nets, Damage to the Red Blood Cell Membranes Causing Acanthocytosis and the 'Corona Effect' of a COVID (SARS) Antibody Positive Patient [11].

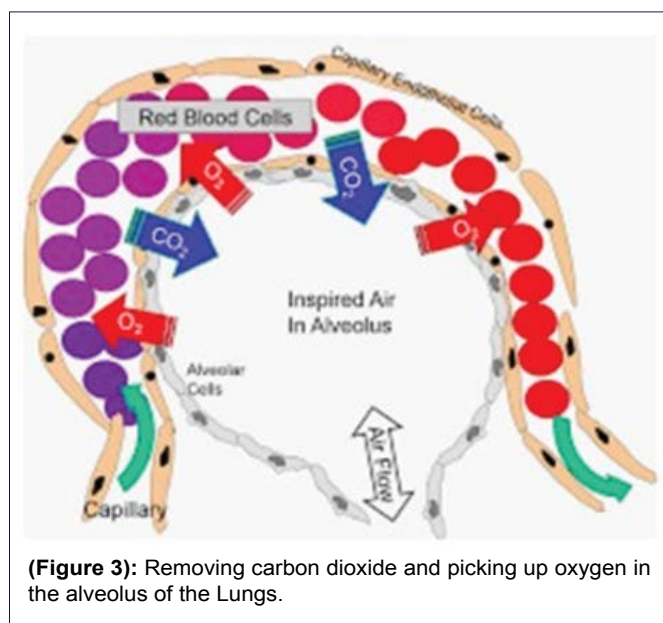
the alveoli this will cause oxygen deprivation that leads to red blood cell hypoxia (carbon dioxide poisoning) degeneration, genetic mutation, sepsis and sudden death [4] [6,7].

What should healthy red blood cells look like?

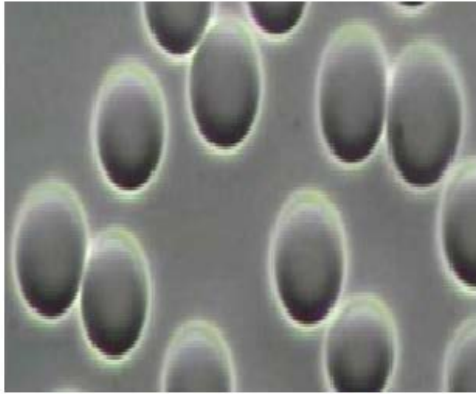
Normal healthy red blood cells should be even in color, even in shape and finally even in size (Figure 5- See Phase Contrast Micrograph 5). Keeping the red bloods cells separated is critical so they can enter the pulmonary capillaries that lead to the alveolus sacs where the red blood cells eliminates acidic waste of carbon dioxide and lactic acid and adsorb and then absorb life-giving oxygen into the hemoglobin molecule. The following phase contrast micrograph is what normal healthy red blood cells should look like! [4, 8-10] (Figure 6).

What are the symptoms of pathological blood coagulation & SARS-CoV-2 & 12? (Figure 7) [11-13]

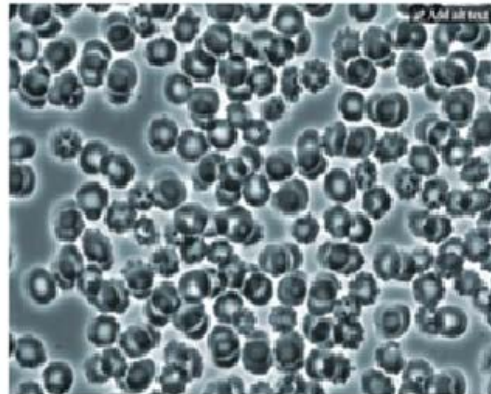
1. Cold hands and cold feet
2. Light headedness
3. Muddled thinking
4. Neuropathy of the extremities
5. Tingling in the toes



(Figure 3): Removing carbon dioxide and picking up oxygen in the alveolus of the Lungs.

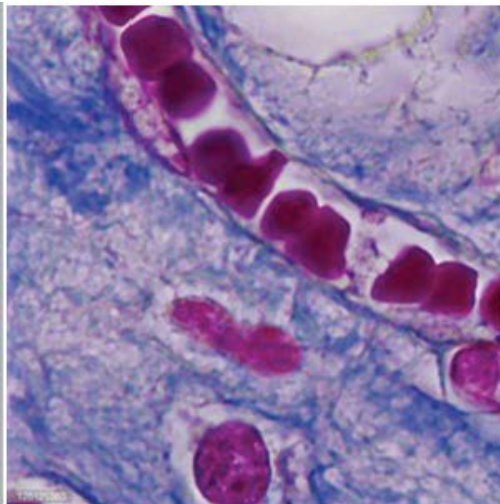


Phase Contrast Micrograph 5

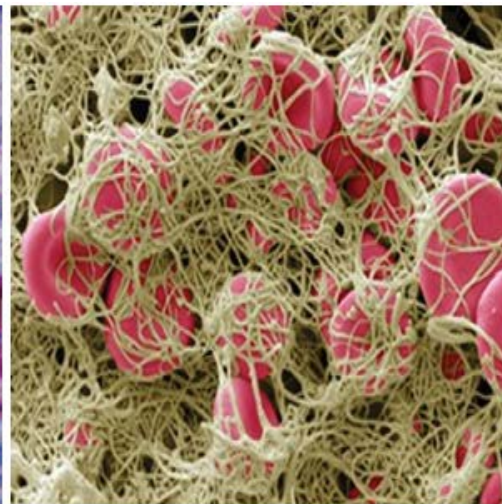


Phase Contrast Micrograph 8

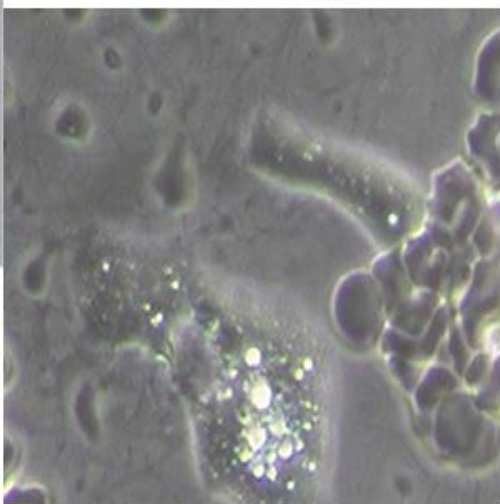
(Figure 5): Phase Contrast Micrograph 5 - Normal Healthy Red Blood Cells [9]. Phase Contrast Micrograph 8 - Micrograph of Targeted Red Blood cells with 'Corona Effect' Indicating Oxygen Deprivation and Radiation Poisoning



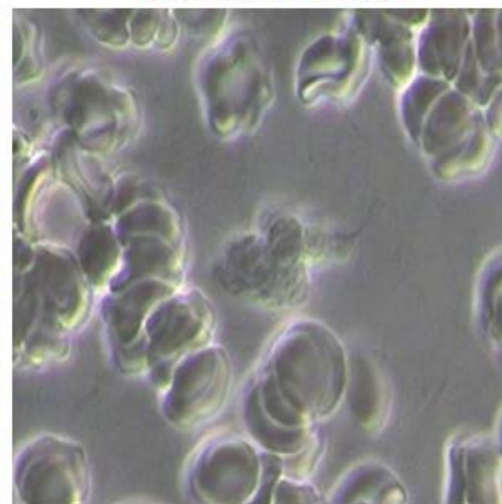
Phase Contrast Micrograph 1



Phase Contrast Micrograph 2

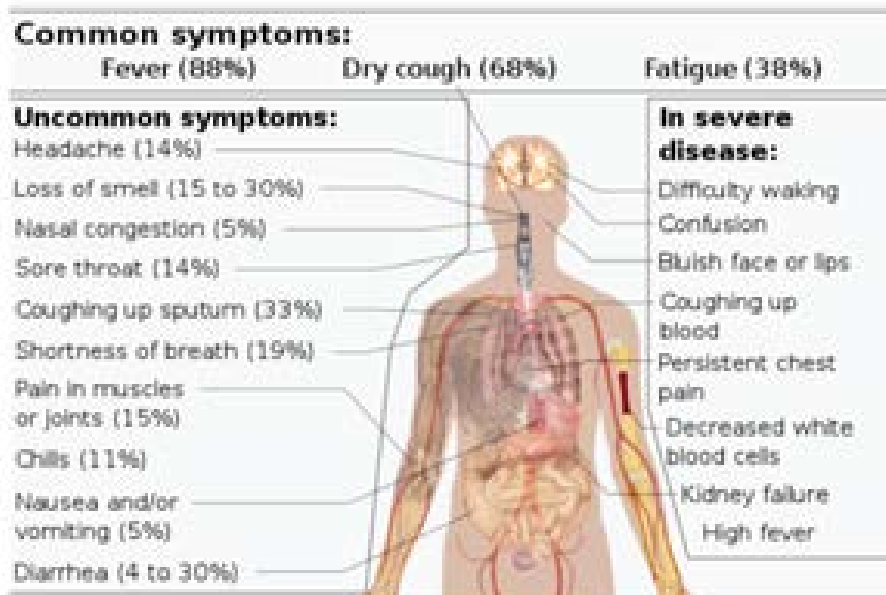


Phase Contrast Micrograph 6



Phase Contrast Micrograph 7

(Figure 6): Phase Contrast Micrograph 1 - Red Blood Cells Travel Single File in the Capillaries to the Alveoli of the Lungs. Phase Contrast Micrograph 2 - Erythrocytic Fibrin Net Indicating Disseminated Intravascular Coagulation – DIC. Phase Contrast Micrograph 6: Shistocytes or Cell Fragments, Damaged Neutrophil (WBC) with lactic and citric acid crystals and Pathological Blood Coagulation [10]. Phase Contrast Micrograph 7: Live Blood Cell Analysis Showing DIC, Thrombosis, Immature Neutrophils, the 'Corona Effect' and Acanthocytosis.



(Figure 7): Symptoms of Pathological Blood Coagulation & SARS-CoV-2 & 12?

6. Dry cough
7. Frequent cough
8. Wheezing
9. Choking sensation
10. Waking up out of breath
11. Bluish discoloration of the skin
12. Shortness of breath while resting
13. Severe shortness of breath after physical activity
14. Fever
15. Shortness of breath
16. Low energy
17. Fatigue
18. Blurred vision
19. Hearing loss
20. Loss of taste
21. Night sweats
22. Aches or pains in the muscles
23. Joint Pain
24. Dizziness
25. Itching
26. Skin blemishes
27. Nausea
28. Bowel irritation and elimination problems
29. Hypoxia

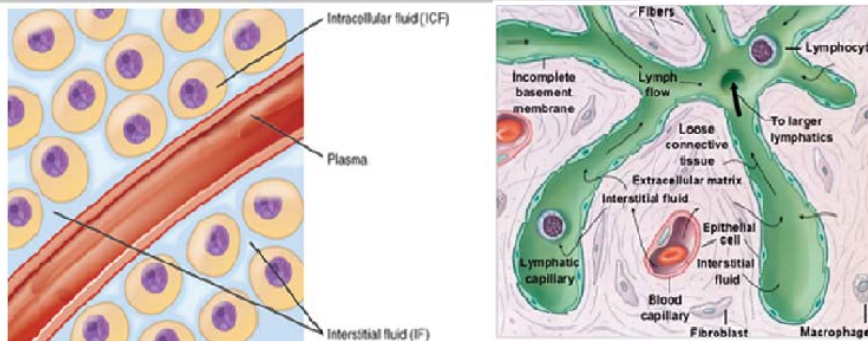
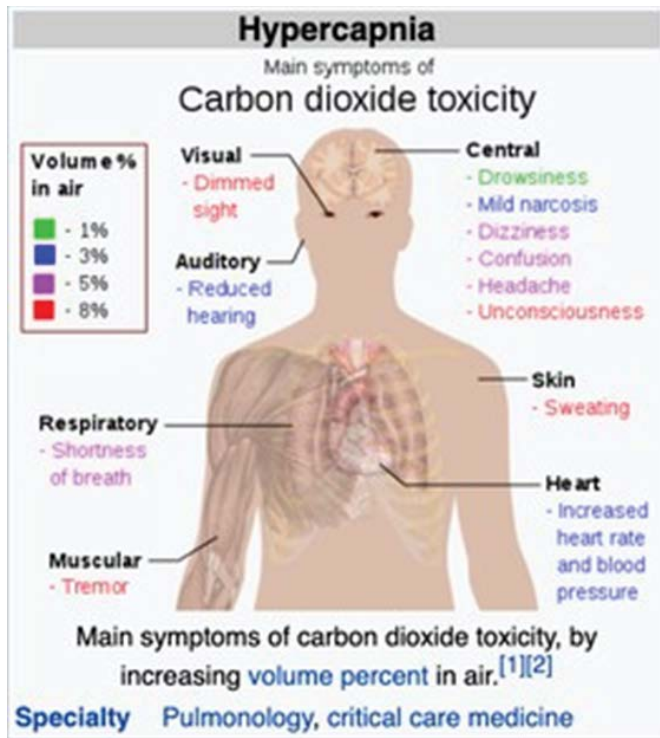
30. Hypoxemic
31. Hypercapnia

What are the Major Contributing Factors or the Causes for Pathological Blood Coagulation or Disseminated Intravascular Coagulation (DIC) and Then Severe Acute Respiratory Syndrome/Coronavirus (SARS-CoV)?

Decompensated acidosis of the body fluids causes erythrocytic or red blood cell membrane degeneration and genetic mutation causing the conditions of rouleau, membrane degeneration causing the spiking or knobbing or ‘Corona Effect’, acanthocytosis, erythrocytic symplasmism or red blood cell clotting, thrombosis and Disseminated Intravascular Coagulation (DIC). There are at least seven major contributing toxic factors that cause the increased levels of acidity in the body fluids leading to a significant decline in the alkaline design of the major body fluids (Figure 8: Interstitial fluids of the Interstitium organ, the intravascular fluids and the Intracellular fluids) from their ideal pH of 7.365 to an unhealthy pH of 7.265 to 7.165.

The eight major contributing acidic factors to pathological blood coagulation (DIC) and Lung Disease (SARS - CoV) are:

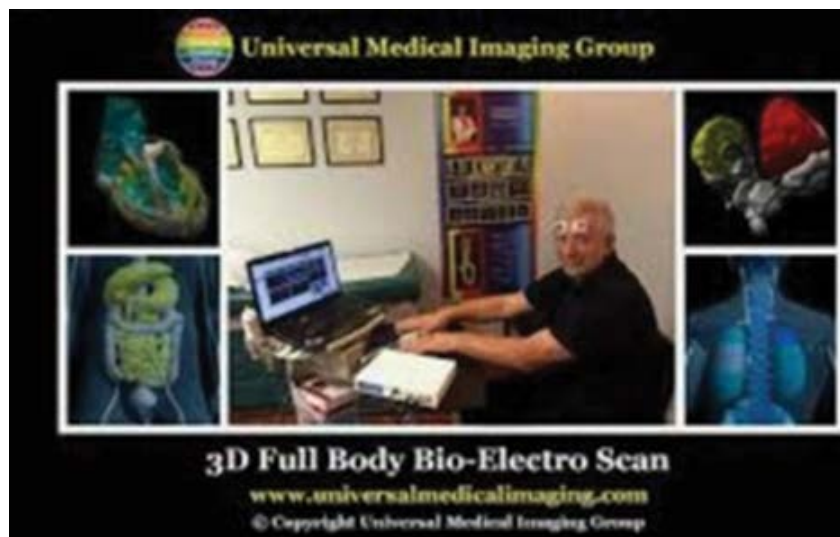1. Pulsating electro-magnetic fields from satellites, cell phones, computers, cell towers, WiFi, electric cars, TV’s, etc., [14-16].
2. Carbon dioxide, carbon monoxide and methane gas poisoning from air- pollution (Figure 9). [17-22]
3. Cell Membrane Degeneration causing Pathological blood coagulation leading to hypoxia, interstitial lung disease (SARS and MERS), sepsis and death [23-24].
4. Glyphosate poisoning from food, water [24, 25].



(Figure 8): The Three Major Fluids of the Human Body - Intravascular, Interstitial and Intracellular.



(Figure 9): Chemical trail air pollution



(Figure 10): The 3-D Full Body Bio-Electro Scanning Test.

5. Acidic poisoning from Influenza vaccinations [24, 25].
6. Lactic and citric acid poisoning from diet, metabolism and yeast/fungi [26, 27].
7. Uric, nitric, sulphuric and phosphoric acid poisoning from indigestion of eggs, fish, beef, chicken and pork [26, 27].
8. The introduction of genetically modified organisms and aluminum oxide and mercury poisoning from vaccines and chem trails (See Phase Contrast Micrograph 6) [26, 27, and 22].

Methodology for Determining Pathological Blood Coagulation (DIC) and Lung Disease (SARS-CoV)

Live and Dried Blood smears are both non-invasive blood tests that were used in viewing anatomically the conditions of the red and white blood cells in Disseminated Intravascular Coagulation (DIC), Thrombosis, Rouleau, the ‘Corona Effect’ and Acanthocytosis. (See Phase Contrast Micrograph 7) [4].

Using ultrasound for anatomical testing during autopsy was also used to show pathological blood coagulation and pulmonary thrombosis as the possible leading cause for oxygen deprivation, hypoxia and finally death [28].

Non-Invasive Diagnostic Intravascular and Interstitial Fluid Testing

In addition, we used our unique patent-pending non-invasive 3-D Bio-electro-scanning and non-invasive intravascular blood testing devices for testing and quantifying the biochemistry, including the pH of the intracellular fluids, the intravascular fluids and the interstitial fluids of the Interstitium, the largest organ of the human body (Figure 10). By measuring and comparing the biochemistry of all the body fluids it became clear that patients who tested positive for pathological blood

coagulation or disseminated intravascular coagulation and positive SARS-CoV antibodies were all in decompensated acidosis of the interstitial fluids, including the interstitial fluids of the lungs leading to the genesis of oxygen deprivation, hypoxia and sudden death was not viral, bacterial or fungal [28-30].

Conclusion:

After testing the body fluids of thousands of patients over the last seven years exhibiting pathological blood coagulation (DIC) we have concluded that the cause of oxygen deprivation of blood and lungs, red blood cell degeneration, DIC, thrombosis, hypoxia, severe acute respiratory syndrome or SARS-CoV and sudden death is due to decompensated acidosis of the intravascular fluids and the interstitial fluids of the Interstitium organ [28].

References

1. Hamilton PJ (1978) Disseminated Intravascular Coagulation: A Review. *Journal of Clinical Pathology* 31: 609. [\[View Article\]](#)
2. Alveolus- Merriam-Webster.com Dictionary, Merriam-Webster. [\[View\]](#)
3. Dezube R (2019) Exchanging Oxygen and Carbon Dioxide. *Merck Manuals* [\[View Article\]](#)
4. Young RO (2016) Pathological Blood Coagulation and the Mycotoxic Oxidative Stress Test (MOST). *Int J Vaccines Vaccin* 2: 00048. [\[View Article\]](#)
5. Tang N, Li D, Wang X, Sun Z (2020) Abnormal coagulation parameters are associated with poor prognosis in patients with novel coronavirus pneumonia. *J Thromb Haemost* 18(4):844–7. [\[View Article\]](#)
6. Fox News (2020) Silent hypoxia may be killing COVID-19 patients, but there’s hope 28 Apr. 2020. [\[View Article\]](#)
7. Ryu JH, Olson EJ, Midthun DE, Swensen SJ (2002) Diagnostic approach to the patient with diffuse lung disease *Mayo Clinic Proceedings* 77: 1221-122. [\[View Article\]](#)

8. Ding Y, Wang H, Shen H, Li Z, Geng J, et al. (2003) The clinical pathology of Severe Acute Respiratory Syndrome (SARS): a report from China. *J Pathol* 200: 282-289. [[View Article](#)]
9. Young RO (2001) Sick and Tired, Reclaim Your Inner Terrain-Woodland Publishing. [[View Article](#)]
10. Young RO (2016) Nutritional Cellular Microscopy: Live and Dried Blood Profiles Hikari Omni Media. [[View Article](#)]
11. Young (2016) Plant-based alkaline diet decreases heart disease risk by 40% and blocked arteries by 90%. [[View Article](#)]
12. Smith DG (2020) Coronavirus May Be a Blood Vessel Disease, Which Explains Everything. *M-Experimental*. [[View Article](#)]
13. Hariri L, Hardin CC (2020) Covid-19, Angiogenesis, and ARDS Endotypes. *N Engl J Med*. [[View Article](#)]
14. Rubik B (1997) Bioelectromagnetic Medicine. *Administrative Radiology Journal* XVI (8) 38-46. [[View Article](#)]
15. Young RO (2016) The Effects of ElectroMagnetic Frequencies (EMF) on the Blood and Biological Terrain. [[View Article](#)]
16. Young RO (2020) Adverse Health Effects of 5G Mobile Networking Technology Under Real-Life Conditions. [[View Article](#)]
17. NOAA (2016) In a high carbon dioxide world, dangerous waters ahead. [[View Article](#)]
18. NOAA (2018) What is Ocean Acidification? [[View Article](#)]
19. National Geographic (2017) Ocean Acidification. [[View Article](#)]
20. NOAA (2010) Ocean Acidification, Today and in the Future. [[View Article](#)]
21. Young RO, Young SR (2010) The pH Miracle Revised and Updated. *Hachett Publishing*. [[View Article](#)]
22. Young RO (2019) Are the Interstitial Fluids Raining Acid on YOUR Lung Cells? [[View Article](#)]
23. Young RO, Migalko G (2020) Interstitial Fluid Lung Disease (IFLD) of the Interstitium Organ the Cause and Self-Care to a Self-Cure for Lung Disease. *International Journal of Cancer Research & Therapy*. [[View Article](#)]
24. Thompson BT, Chambers RC, Liu KD (2017) Acute respiratory distress syndrome. *N Engl J Med* 377:562-572. [[View Article](#)]
25. Young RO Sick and Tired [[View Article](#)]
26. Young RO, Young SR (2010) The pH Miracle Revised and Updated. *Grand Central Publishing*. [[View Article](#)]
27. Vaccines Today (2020) EU and World meter. [[View Article](#)]
28. Duarte-Neto AN, de Almedia Monterio RA, da Silva LF, Malheiros DMAC, de Oliveira EP, et. al. (2020) Pulmonary and systemic involvement of COVID- 19 assessed by ultrasound-guided minimally invasive autopsy. *Histopathology*. [[View Article](#)]
29. Young RO (2016) Second Thoughts about Viruses, Vaccines, and the HIV/AIDS Hypothesis. *Hikari Omni Media*. [[View Article](#)]
30. Young RO (2016) The Possible Cause of Polio, Post-Polio, CNS, PVIIPD, Legionnaires, AIDS and the Cancer Epidemic - Mass Acidic Chemical Poisoning? *Hikari Omni Media* [[View Article](#)]

Citation: Young RO, Migalko G (2020) What Causes Oxygen Deprivation of the Blood(DIC) and Then Lungs(SARS - CoV 2 & 12)?. *Integ Mol Bio Biotechnol* 1: 001-007.

Copyright: © 2020 Young RO, et al. This is an open-access article distributed under the terms of the Creative Commons Attribution License, which permits unrestricted use, distribution, and reproduction in any medium, provided the original author and source are credited.
